

## A New Incisional Approach to the Rheumatoid Foot

*The authors introduce a new incisional approach to surgery of the rheumatoid foot. Advantages and disadvantages are presented. Historical comparisons are discussed, along with refinement of techniques for pan metatarsal head resection.*

The rheumatoid foot remains one of the most challenging yet rewarding surgical procedures performed. As foot surgeons, it is imperative to possess a thorough knowledge of all incisional approaches available. One must also understand the inherent complications and sequelae that can result from these surgeries. The podiatric surgical community has rejected the transverse plantar and dorsal incisional approaches first described by Hoffman (1) and Clayton (2). Many authors have modified these transverse incisions to include proximal phalangeal base removal or even digital amputation (35).

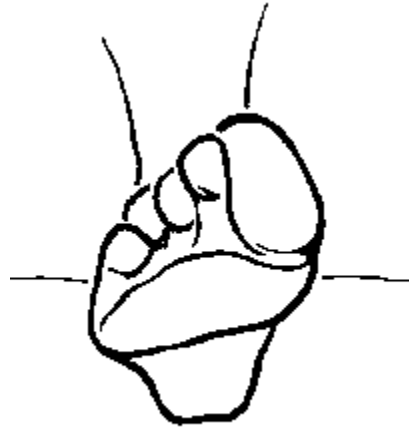

Figure 1. The Hoffmar incision (1911).

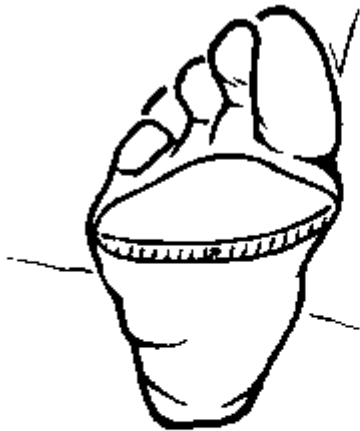

Figure 2. The Fowler incision (1958). The plantar ellipse is used to pull the fat pad proximally.

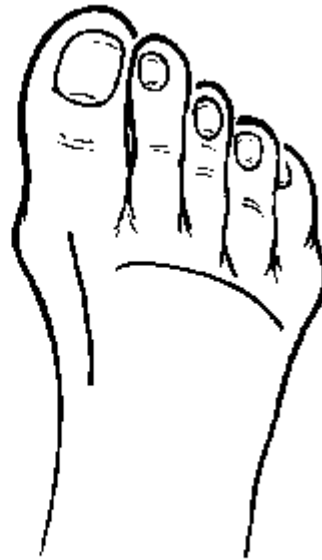

Figure 4. Modification of the Clayton procedure with a Keeler arthroplasty.

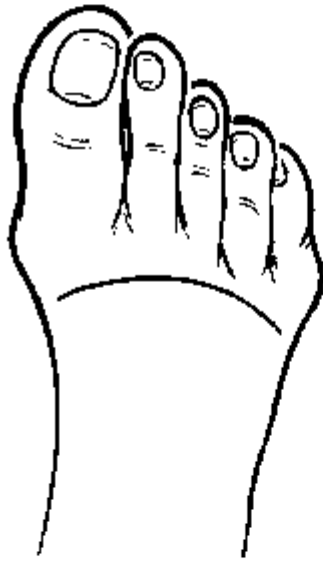

Figure 3. The Clayton incision (1960).

cut with difficulty preserving the metatarsophalangeal joint capsule and periosteum.

Conclusion: A good procedure for mild rheumatoid foot with minimal digital subluxation, however, the second and fifth metatarsophalangeal joints cannot be addressed without damage to skin and vital tissues.

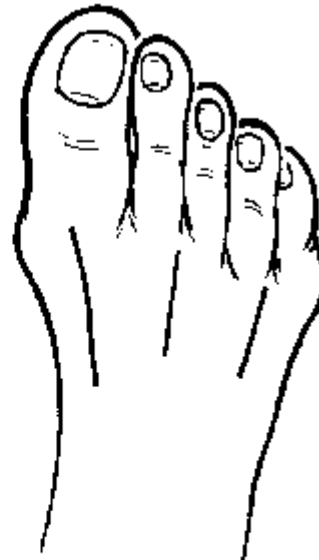

Figure 5. The Larron incision (1951); the traditional three-incisional (metatarsal) approach.

Figures 1 through 4 illustrate the more commonly used incisions described prior to 1951(6). The authors submit that all four incisions usually resulted in loss of function, severe morbidity, chronic edema, complicated postoperative course and poor cosmesis. In spite of the improvements and modifications illustrated, they all remain primarily salvage procedures for painfully deformed rheumatoid feet.

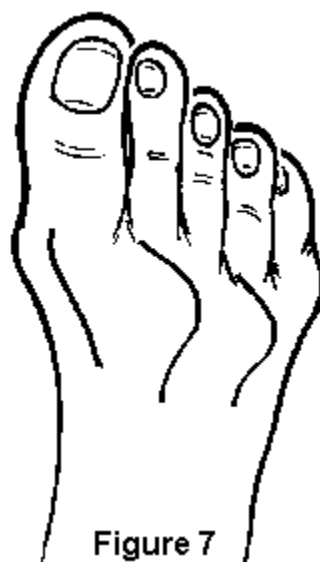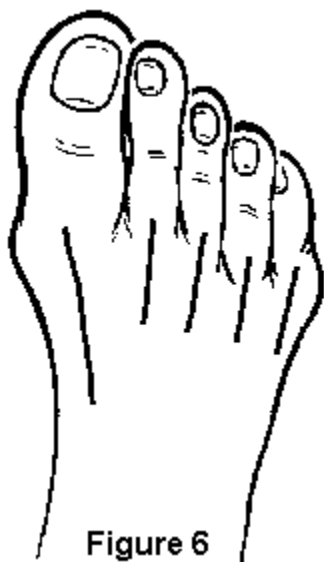Larmon (7) advocated the three longitudinal linear incisional approach to the rheumatoid foot: *i.e.*, overlying the first metatarsophalangeal joint (similar to Keller arthroplasty), then two dorsal incisions within the second and fourth metatarsal interspaces. Although he advocated removing the phalangeal bases, he was the first to abandon the transverse approach. Larmon's logic behind this procedure was to allow for maximum tissue exposure with minimal trauma to surrounding vital structures. This procedure was popular until 1983 when Hodor and Dobbs (6) introduced the five incision approach to the rheumatoid foot. This modification addressed each individual metatarsophalangeal joint separately, through five overlying dorsal linear incisions. Both procedures were major modifications. They provided significant improvements in tissue exposure and decreased patient morbidity. However, the three and five incisional approaches are not without draw backs and potential complications. The authors compare their new modifications with the Larmon (7) - three incisional, and the Hodor and Dobbs (6) - five incisional approaches. Advantages and disadvantages of each are discussed.

**Larmon - Three Linear Dorsal Incisions (Fig. 5)**

**Advantages:** Postoperative scar contracture does not affect the digits, early ambulation postoperatively, limited morbidity with simple wound management, and good cosmesis.

**Disadvantages:** Limited surgical exposure to metatarsal heads, high incidence of injury to intermetatarsal neurovascular structures, and large surgical tissue deficit with difficulty preserving the metatarsophalangeal joint capsule and periosteum .

**Conclusion:** A good procedure for mild rheumatoid foot with minimal digital subluxation, however the second and fifth metatarsophalangeal joints cannot be addressed without damage to skin and vital tissues.



**Hodor and  
Dobbs - Five  
Incisional**

**Approach (Fig.6)**

**Advantages:** Provides good access to metatarsophalangeal joints, adequate tissue exposure with minimal damage to neurovascular structures, early ambulation with limited postoperative morbidity, good preservation of capsular and periosteal tissues (minimal deadspace postoperatively) and good cosmesis.

**Disadvantages:** Skin incisions are in close proximity to one another, especially when metatarsus adductus is present, higher incidence of skin slough, and scar contractions are linear, and may contribute to recontraction of the digits postoperatively.

**Conclusion:** Used primarily by the authors with fair results, however, the incisions are often in very close proximity - covering and diverging to accommodate metatarsus adductus. This leads to possible tissue necrosis. Scar contraction is an often postoperative complication and contributes to unwanted loss of digital position.

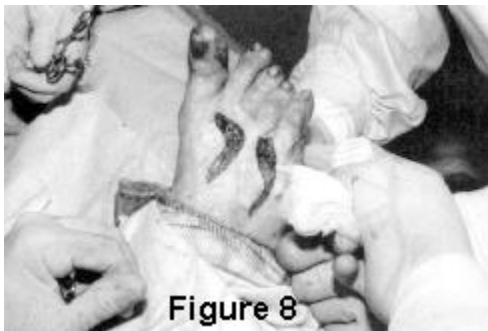**New Approach - One Linear Two Lazy "S" Incisions**

**Procedure**

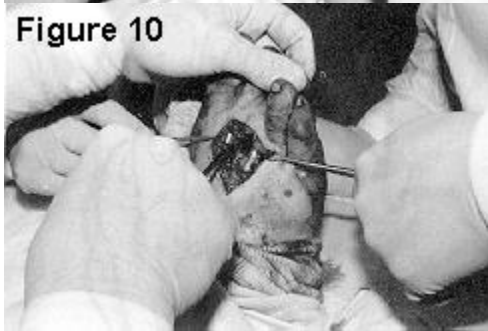
The first incision is consistent with the Keller arthroplasty. The surgeon may elect to resect the proximal . The new surgical approach; two lazy "S" incisions for lesser metatarsal head exposure and excision. The Keller incision is the third incision and may be staged depending upon the severity of the patient's deformity.phalangeal base of the hallux with or without first metatarsal head resection or remodeling. The authors prefer "U" flap capsular closure without fixation whenever possible; however, single Kirschner wire fixation and purse string capsular closure is also acceptable. The lesser metatarsophalangeal joints can present a difficult challenge during rheumatoid foot surgery. These joints are destroyed by hypertrophic synovial tissue or pannus formation. They are often painfully dislocated, being pushed through the plantar aspect of the foot by subluxed digits. The following procedure is useful for pan metatarsal resection with or without Keller arthroplasty. It can also be used for multiple metatarsal osteotomies and for partial or total metatarsal head resection.

**Second Incision.**

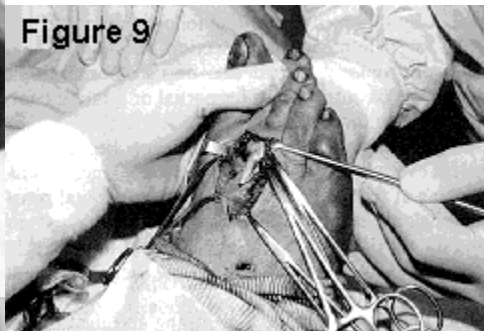
The second incision begins distal medial, overlying the second metatarsophalangeal joint, initiating at the medial base of the second digital proximal phalanx. It then progresses inferior laterally overlying the third metatarsophalangeal joint. It extends in a lazy "S"



**Figure 8**



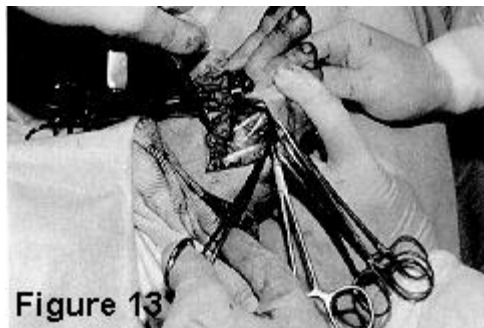
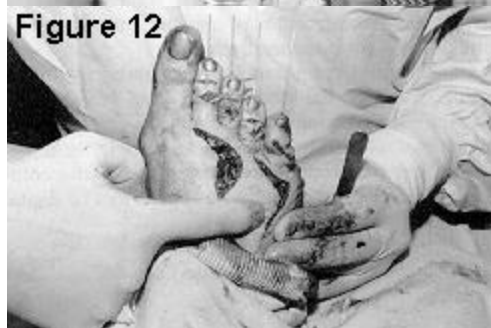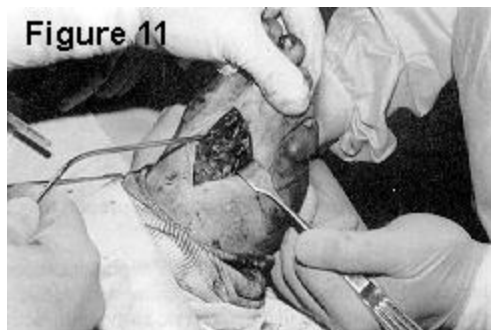
**Figure 10**



**Figure 9**

pattern and proceeds along the medial shaft of the third metatarsal (Figs. 7, 8). The incision is deepened, clamping and ligating the dorsal venous structures as necessary. Adequate

subcutaneous tissue must be preserved in order to maintain a viable skin flap. Once skin exposure has been obtained, extensor digitorum longus tenectomies (approximately 1 cm. of tendon) are performed. The extensor digitorum brevis tendons are preserved (Figs. 9, 10,). Each metatarsophalangeal joint is then addressed individually be separate capsular incisions



(Fig. 11). Capsular-

periosteal incisions are performed over the second and third metatarsophalangeal joints.

#### **Third Incision.**

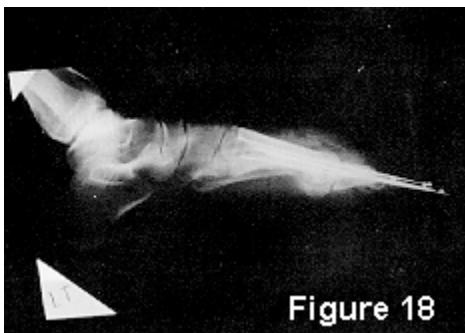
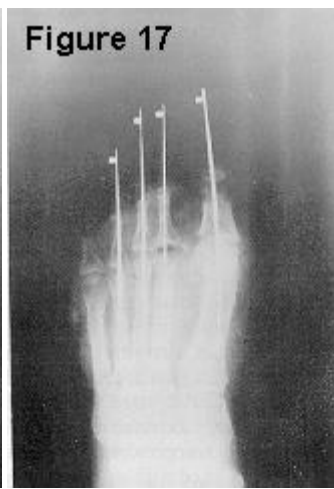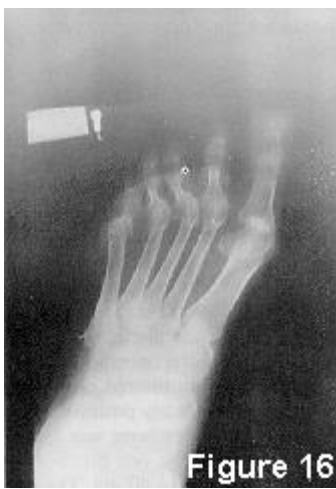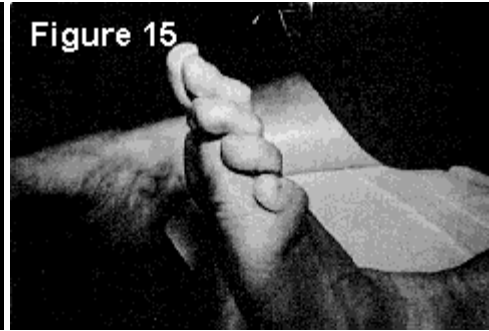
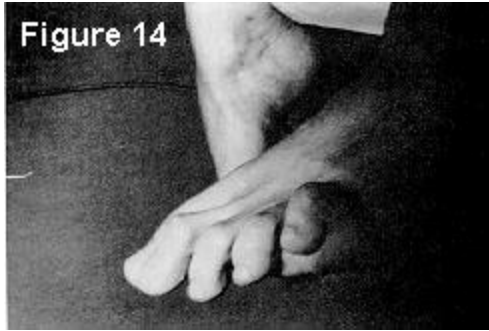In similar fashion to the second, this incision begins at the medial base of the fourth digital phalanx and proceeds inferior laterally (almost transversely) to the middle of the fifth metatarsophalangeal joint. The incision then curves in a lazy "S" fashion and continues along the medial shaft of the fifth metatarsal (7-12). The wound is now deepened avoiding or ligating superficial vessels. Once again, great care is taken to preserve the tissue underlying the flap and skin is relected and retracted. The long extensor tendons are again identified and tenectomies are performed. The extensor digitorum brevis tendon to the fourth digit is left intact (Fig. 13). Each metatarsophalangeal joint is again addressed individually, and capsular tissue tagged for later closure.

Metatarsal head resection with maintenance of parabolic length is mandatory and easily visualized through both incisions. Digital fusion with preservation of all phalangeal bases is performed on digits 2, 3, and 4. Kirschner wire fixation of these digits is recommended including Kirschner wire stabilization of the fifth digit arthroplasty (Fig. 12). The 0.045 inch Kirschner wires are advanced through each respective metatarsal medullary canal and into the metatarsal bases. Usually this provides good stabilization and retraction of surgical dead spaces. In most cases, a surgical drain is not needed providing each metatarsophalangeal joint has been carefully closed and purse stringed. After closing each individual joint capsule, subcutaneous tissue is affected with meticulous care to re-approximate adjacent tissues. Skin edges should be closed with minimal tension. The authors strongly recommend simple interrupted prolene sutures to allow for edematous expansion as well as suture release should it be needed postoperatively. A large gauze dressing is needed as well as mild compressive dressing to control edema. Postoperative shoe with crutches or walker for stability with ambulation is acceptable.

**Advantages:** Provides for maximum tissue exposure, preservation of vital intermetatarsal neurovascular structures, minimal tissue deficit postoperatively, scar contracture does not alter postoperative position of the lesser digits, early ambulation, minimal morbidity, and good cosmesis.

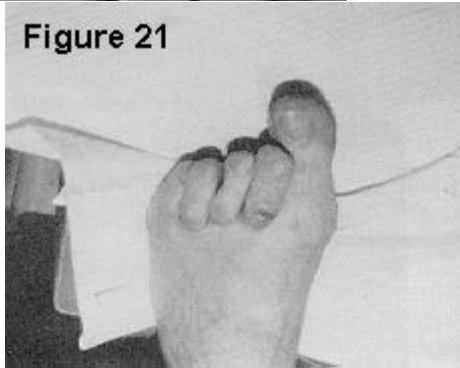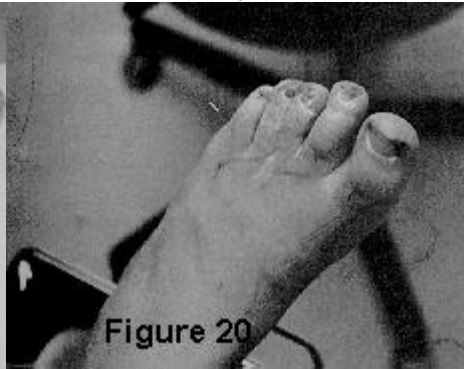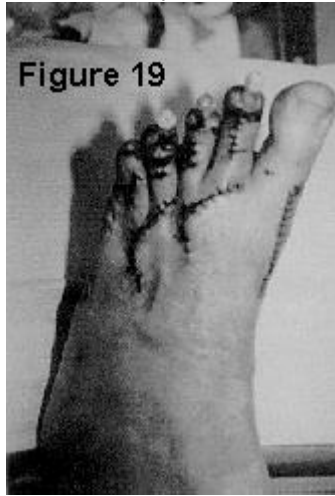**Disadvantages:** Technically difficult to perform, requires meticulous handling of tissue, incisions require careful planning prior to surgery, and tedious suturing time is required.

#### **Case Presentations**



Figures 14 and 15 are the preoperative photographs of a 39 year old rheumatoid arthritic female. The digital contraction with subsequent retrograde buckling, plantar displacement of the lesser metatarsals and pannus formation is responsible for her chronically painful fore foot. Figure 16 is the preoperative anteroposterior radiograph; clearly illustrating significant metatarsophalangeal joint destruction. Preoperatively the patient had been maintained on oral prednisone (15 mg. daily) for 14 months. On call to the operating room, 100 mg. of hydrocortisone was administered intravenously. Intraoperatively, and immediately postoperatively an additional 100 mg. of hydrocortisone was again infused. On the first postoperative day, oral prednisone therapy resumed and was increased to 40 mg. The patient was discharged from the hospital with a tapered oral prednisone regiment of 30 mg. for 3 days, 20 mg. for 2 days, and resumption of her 15mg. daily dosage. The patient was also given a prescription for acetaminophen with codeine #3 if needed for pain. She presented postoperatively at 3 and 7 day intervals with minimal edema or pain. Postoperative x-rays (Figs. 17 and 18) demonstrate the maintenance of the metatarsal parabola as well as Kirschner wire fixation into the metatarsal bases. In this individual a 0.062inch Kirschner wire and "U" flap capsular closure were used for the Keller arthroplasty, as well as minimal bone removal on the fifth metatarsal head. These modifications are the surgeon's preference for this patient; however, the surgical incision allows for

maximum exposure and visualization for intraoperative



decisions.

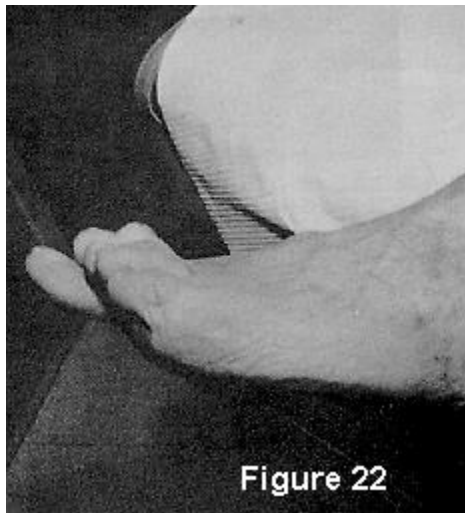


Figure 19 is a 3 week postoperative photograph. The Kirschner wire was removed from the first metatarsophalangeal joint at 2 weeks to allow for early mobilization of the joint. The lesser 0.045 inch Kirschner wires will be removed at 5 weeks in order to provide adequate stabilization and subsequent fusion of digits 2, 3, and 4. The patient was able to ambulate unassisted at 8 weeks in athletic shoes and was without fore foot pain. Figure 20 is a postoperative photograph taken 1 year later. The patient was ambulating comfortably and presented for surgery of her right foot. Four years postoperatively, she is able to wear conventional shoes with comfort, and remains free of foot pain.

Figures 21 and 22 are preoperative photographs of the left foot of a 47 year-old rheumatoid arthritic female. The patient also found walking unbearably painful; especially under the second and third metatarsophalangeal joint. The preoperative x-rays



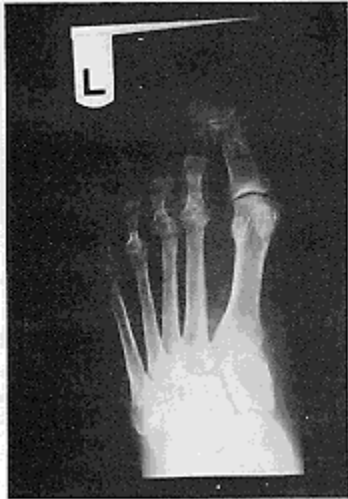

Figure 23. Preoperative radiograph. Note the digits articulate with the metatarsal necks and shafts.

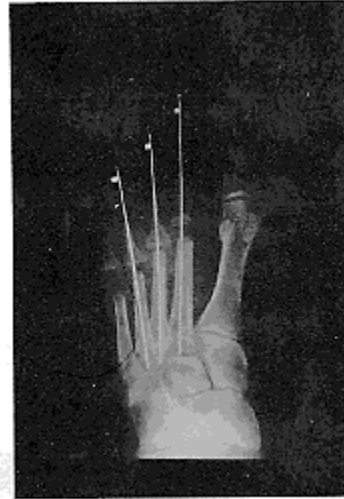

Figure 25. Postoperative radiograph—immediate (antero-posterior).

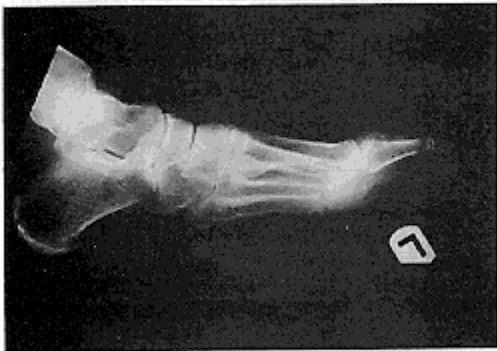


Figure 24. Preoperative radiograph. Note the prominence of the lesser metatarsal heads. The digits are completely subluxed dorsally.

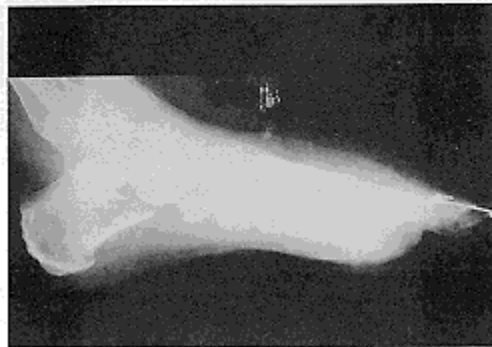


Figure 26. Postoperative radiograph taken through the fore-foot cast (lateral).

(Figures 23,24) clearly substantiate her complaints. Ironically, in spite of the severe damage to her forefoot, the first metatarsophalangeal joint was completely pain free with fair to good range of motion. The patient refused to consent to Keller arthroplasty, which was recommended based on the probable future destruction of this joint. The authors believed recommending Reverdin Laird bunionectomy was inappropriate knowing that the joint would probably require future surgery. Metatarsal head resections of the 2nd, 3rd, 4th, and 5th were performed, as well as digital arthrodesis. The first metatarsophalangeal joint was left intact; however, the patient was advised that she would undergo Keller arthroplasty when needed (Fig. 25). The patient was admitted for same day surgery. Preoperatively, she had been maintained on an oral prednisone dosage of 5 mg. daily. Intraoperatively, 100 mg. of hydrocortisone was administered intravenously. The patient was discharged with an oral

(Figures

prednisone regiment of 20 mg. for 2 days;10 mg. for 2 days, and resumption of her daily 5mg. dose

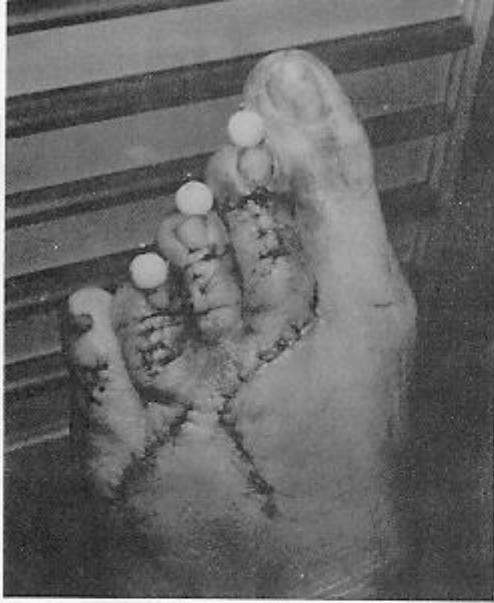


Figure 27. 3rd postoperative day.

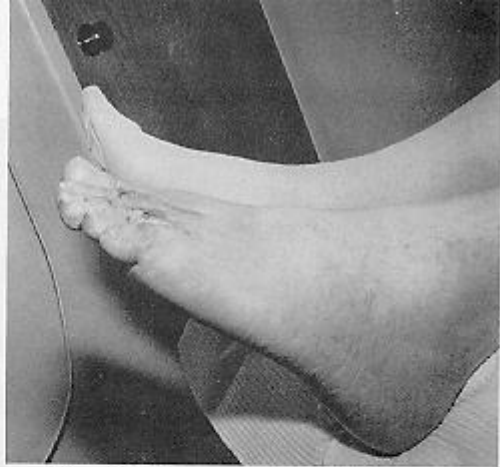
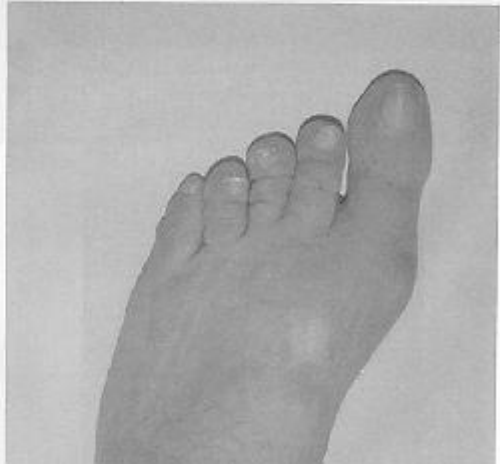
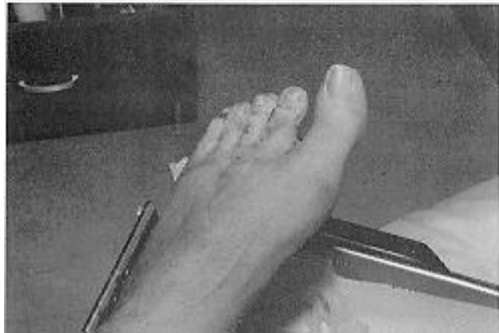Figure 29. 6th postoperative week (side view).



(Figs. 26, 27).

The 6-week postoperative photograph is shown 1 week after Kirschner wire removal (Figs. 28, 29). Figure 30 was taken 14 months postoperatively. The first metatarsophalangeal joint is functional and

asymptomatic. This weight bearing photograph illustrates good cosmesis obtained from this incisional

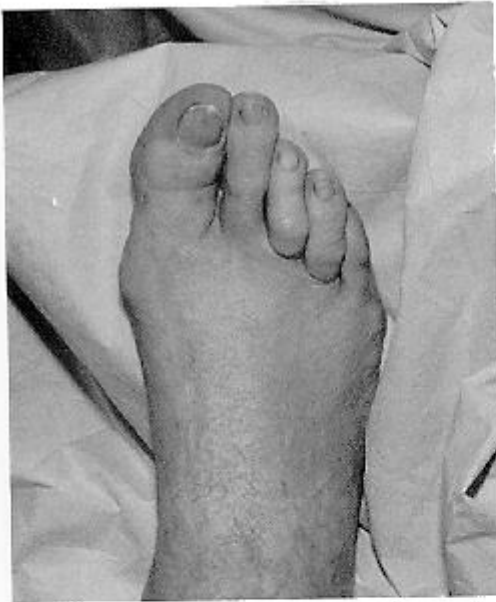


Figure 31. Preoperative photograph.

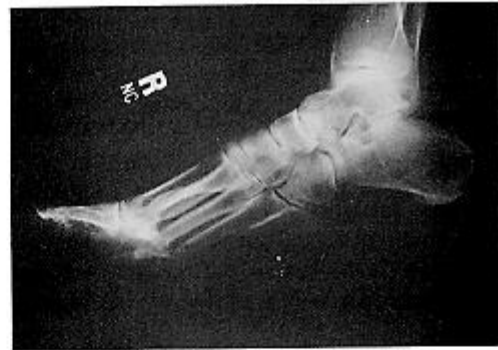


Figure 33. Preoperative radiograph. Note the metatarsophalangeal joint destruction.

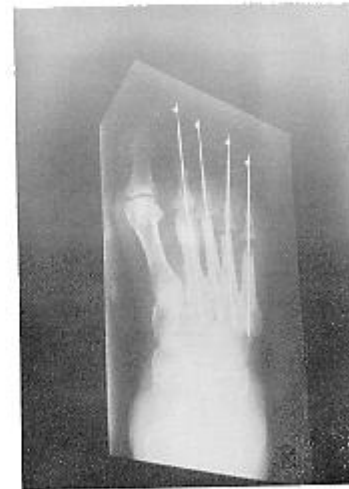
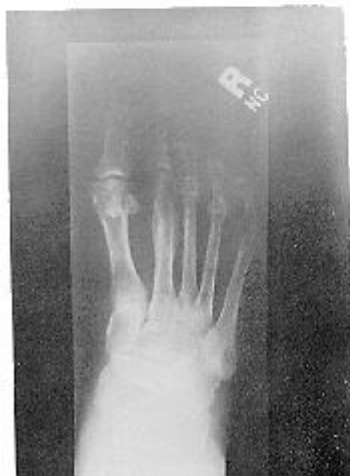
Figure 34. Postoperative radiograph—immediately (anteroposterior).



approach.

Figures 31-33 are the preoperative photographs and x-rays of the same patient's right foot 2 years earlier. Evidence of an old second metatarsal stress fracture is seen. The patient's chief complaint was pain under the third and fourth metatarsals as is clearly evident from the dislocations seen on the x-rays. The first metatarsophalangeal joint is again void of major joint destruction and the patient did not consent to Keller arthroplasty. In addition to her chief complaint, she also complains of a prominent and painful tailor's bunion. Intraoperatively, the fifth metatarsal head resection resulted in considerable bone removal and dead space. A 0.045-inch Kirschner wire was introduced through the fifth digit arthroplasty to maintain stability and the capsule interposed to prevent hematoma (as evidenced by postoperative radiographs, Fig's.34

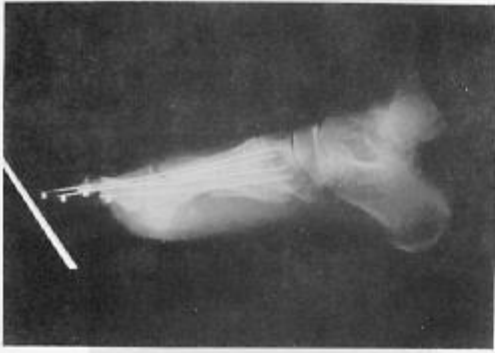


Figure 35. Postoperative radiograph—immediately (lateral).

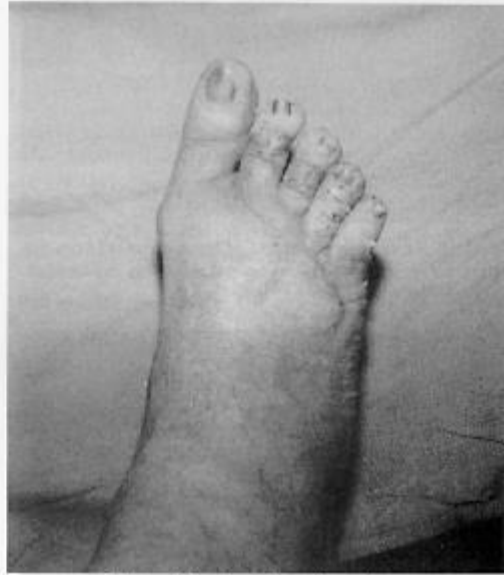


Figure 37. 1 month postoperative.

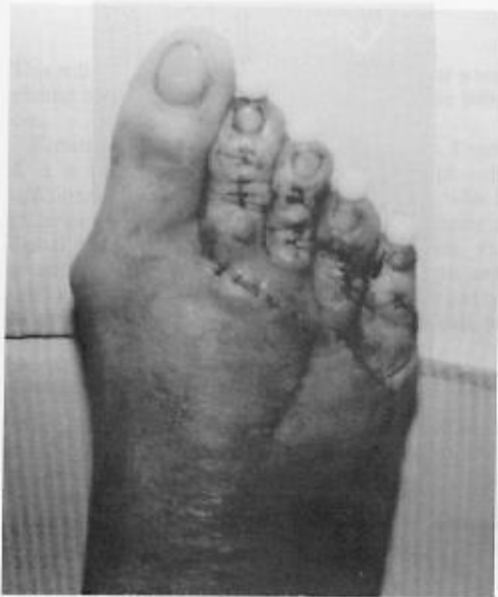


Figure 36. 1st week postoperative.

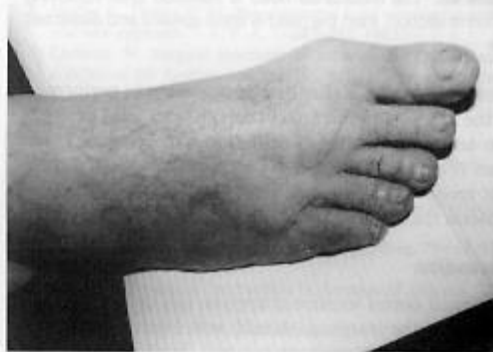
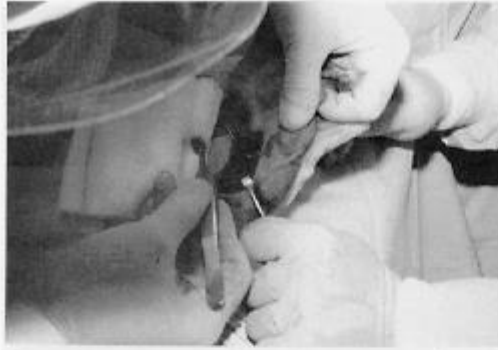
Figure 38. 5 months postoperative.

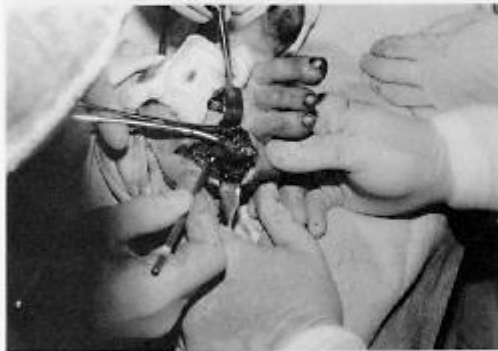and 35 and the 1-week postoperative photograph Fig. 36). Figures 37 and 38 represent 1-month and 5-month follow-up photographs of the patient's right foot ([Fig's 39, 40](#)).

At 8 months postoperatively, the patient related increasing pain and misalignment of her left first metatarsophalangeal joint and toe, respectively. She also became increasingly concerned her right toe would follow the same course. At 8 months postoperatively for the right foot, the patient elected to

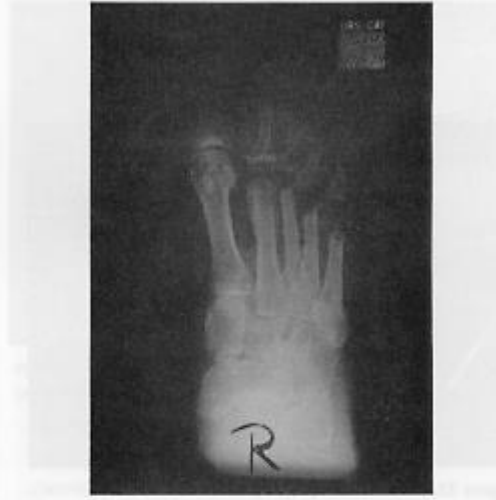bilateral metatarsophalangeal joint destructive



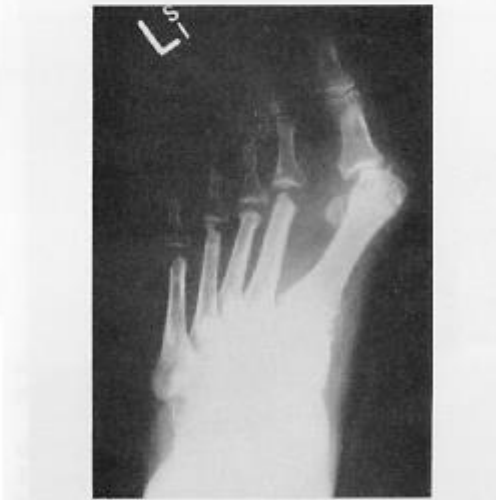**Figure 39.** Note a small section of bone removed from the metatarsal neck prior to clamping and removing the metatarsal head.



**Figure 40.** The metatarsal head is clamped after removing the bone section, then the head is tilted upward and dissected free.



**Figure 41.** Preoperative radiograph, right foot (anteroposterior).



**Figure 42.** Preoperative radiograph, left foot (anteroposterior).

procedures.

Figure 41 represents the postoperative photograph of both feet. Keller arthroplasty was performed on the right foot. Austin-Keller bunionectomy was performed on the left foot due to an increase in both joint destruction and first metatarsal deviation over the past three years (Fig. 42). The authors recommend staging forefoot reconstruction when patients present with severe bilateral rheumatoid foot pain.

### Discussion

In most dorsal incisional approaches to the rheumatoid foot, the surgeon should not expect to clearly visualize the metatarsophalangeal joint spaces. The joints are usually occluded by the phalangeal bases which may be articulating with the metatarsal necks or shafts. The deep linear capsular incisions begin on the digital bases and extend onto the metatarsal shafts. It is imperative to palpate bone beneath the soft tissue prior to cutting. When attempting metatarsal head removal, the metatarsal should be cut longer than desired length to facilitate surgical excision. The desired osteotomy is made proximal to the first cut, removing a small section of bone (Fig. 39). The free metatarsal head now has some space to be clamped and tilted into the operative field ( Fig. 40). It is then sharply and carefully dissected out.

This will provide easier metatarsal head removal when plantar adhesions, fibrous and pannus tissue are present. Kirschner wires are removed in 5 to 6 weeks. Digits 2, 3, 4 and 5 are wrapped and splinted to provide additional support. The authors prefer to use 1/4 inch Gauzetex dressing and flexible collodion to create a digital cast. After approximately 8 to 10 weeks, the patient may use a Coban dressing on the digits and forefoot. At this time, a supportive athletic shoe can be worn without discomfort. Normal shoe gear can be resumed after 16 to 20 weeks.

### **Summary**

The new surgical approach to pan metatarsal head resection provides the best of all prior incisions found in the literature. Good wound exposure; individual metatarsal head resection; yet, avoidance of the metatarsal interspaces. Postoperative course and cosmesis are comparable or superior with earlier described approaches. Minimal scar contraction does not contribute to digital recontraction (a common sequelae to the five incisional approach). Skin slough is a rare occurrence if the incisions are performed properly. The rheumatoid foot presents in various grades of severity. The authors recommend surgical intervention for "end stage" or when advanced joint destructive changes are present. Pan metatarsal excision can bestaged as the patient's symptoms present. The authors also recommend digital arthrodesis for both mild and severe rheumatoid feet to prevent recurrence of digital contraction. The surgeon should be familiar with all possible approaches described in the literature and choose that approach most beneficial to the patient.

3. Gauzetex, General Bandages, Inc., Morton Grove, Illinois 60053. 4. Coban, 3M Medical Surgical Division, St. Paul, Minnesota 551441000.

---

### **Acknowledgments**

The authors thank Mr. Robert Klopfer for illustrations, and Umberto Salustro for photographic reproduction.

---

### **References**

1. Hoffmann, P. An operation for severe grades of contracted or clawed toes. *Am. Orthop. Surg.* 9:441-448, 1911.
2. Clayton, M. L. Surgery of the forefoot in rheumatoid arthritis. *Clin. Orthop.* 16: 136 - 140, 1960.
3. Fowler, A. W. A method of forefoot reconstruction. *J. Bone Joint Surg.* 41B:507-513, 1959.
4. Amuso, S. J., Wissinger, H. A., Margolis, H. M., Eisenbeis, C.H., Stolzer, B. L. Metatarsal head resection in the treatment of rheumatoid arthritis. *Clin. Orthop.* 74:94 - 100, 1971.
5. Gschwend, N. Surgical treatment of rheumatoid arthritis, *Operations on the Foot*, pp, 254-260, W. B. Saunders Co., Philadelphia, 1980.
6. Hodor, L., Dobbs, B. M. Pan metatarsal head resection: a review and new approach. *J. A. P. A.* 73:287 - 292, 1983.
7. Larmon, W. Surgical treatment of deformities of rheumatoid arthritis of the forefoot and toes. *Q. Bull. Northwestern Univ. Med. School.* 25:3942, 1951.

---

### **Additional References**

- Barton, N. J. Arthroplasty of the forefoot in rheumatoid arthritis. *J. Bone Joint Surg.* 55B:1261-1263, 1973.
- Gould, N. Surgery of the forepart of the foot in rheumatoid arthritis. *Foot Ankle* 3:173-179, 1982.
- Key, J. A. Surgical revision of arthritic feet. *Am. Surg.* 79:667 - 672, 1950.
- Marmor, L. Resection of the forefoot in rheumatoid arthritis. *Clin. Orthop.* 108:223 - 227, 1975.
- Schwartzmann, J. R. The surgical management of foot deformities in rheumatoid arthritis. *Clin. Orthop.* 36:869-875, 1964.